
Accuracy of a laboratory-based computer implant guiding system

Eitan Barnea, DMD,^a Ido Alt, DMD,^b Roni Kolerman, DMD,^c and Joseph Nissan, DMD,^a
Tel-Aviv, Israel

MAURICE AND GABRIELA GOLDSCHLEGER SCHOOL OF DENTAL MEDICINE, TEL-AVIV UNIVERSITY

Objective. Computer-guided implant placement is a growing treatment modality in partially and totally edentulous patients, though data about the accuracy of some systems for computer-guided surgery is limited. The purpose of this study was to evaluate the accuracy of a laboratory computer-guided system.

Study design. A laboratory-based computer guiding system (M Guide; MIS technologies, Shlomi, Israel) was used to place implants in a fresh sheep mandible. A second computerized tomography (CT) scan was taken after placing the implants. The drill plan figures of the planned implants were positioned using assigned software (Med3D, Heidelberg, Germany) on the second CT scan to compare the implant position with the initial planning. Values representing the implant locations of the original drill plan were compared with that of the placed implants using SPSS software.

Results. Six measurements (3 vertical, 3 horizontal) were made on each implant to assess the deviation from the initial implant planning. A repeated-measurement analysis of variance was performed comparing the location of measurement (center, abutment, apex) and type of deviation (vertical vs. horizontal). The vertical deviation (mean -0.168) was significantly smaller than the horizontal deviation (mean 1.148).

Conclusion. The laboratory computer-based guiding system may be a viable treatment concept for placing implants. (*Oral Surg Oral Med Oral Pathol Oral Radiol Endod* 2010;109:e6-e10)

The use of dental implants is considered to be a predictable procedure with high survival rates.¹⁻³ The protocol for a successful implant is one that demonstrates osseointegration as well as optimal position of the implant for the fabrication of an esthetic and functional restoration.⁴ Advanced planning for future definitive rehabilitation has an impact on esthetics and biomechanics and can actually determine whether the planned prosthesis can be fabricated.⁵ Early knowledge and planning of the patient's anatomy and implant location, diameter, length, and angulations can help avoid iatrogenic damage and has a potential to minimize treatment time and patient discomfort.⁶

Computer-based guiding systems for dental implant placement intend to provide safe, fast, minimally invasive surgery by integrating data of future rehabilitation and the patient's anatomy. Generally, these systems can be divided into navigators and surgical guides.⁷ The surgical guide systems can be further divided into stereolithographic and laboratory based. In the laboratory-based systems, the surgical guide is made by the laboratory from

acrylic. Initially it is used for imaging and then serves as a surgical guide by the aid of a positioning device.⁸

The accuracy of the navigators and stereolithographic guide systems has been investigated and was found to be superior to conventional surgery.⁹ However, deviations were found, mostly in the lateral aspect of the implant apex for the stereolithographic guide systems and in the vertical aspect for navigators.⁹⁻¹⁷ Little information exists regarding the accuracy of the laboratory-based systems.^{6,8} The purpose of the present study was to evaluate the accuracy of a laboratory-based guide system.

MATERIALS AND METHODS

This study used a fresh sheep's mandible in which space of approximately 30 mm exists between the anterior and posterior teeth, presenting a naturally edentulous ridge. Tissues covering the mandibular bone were carefully removed, and impression of the teeth and the edentulous ridge between the anterior and posterior teeth was taken with irreversible hydrocolloid (Kromopan; Lascod Laboratories, Firenze, Italy). A working model was fabricated using dental stone (Quickstone; WhipMix, Louisville, KY). A radiographic guide was made from acrylic resin (Keystone Industries, Cherry Hill, NJ) mixed with barium sulfate (E-Z-EM, Westbury, NY) in a 1:5 ratio (Fig. 1). A radiopaque Lego brick (Lego Company, Billund, Denmark) was attached to the top of the guide. This Lego

^aDepartment of Oral Rehabilitation.

^bDepartment of Periodontology.

^cPrivate practice.

Received for publication Oct 30, 2009; returned for revision Dec 25, 2009; accepted for publication Jan 3, 2010.

1079-2104/\$ - see front matter

© 2010 Mosby, Inc. All rights reserved.

doi:10.1016/j.tripleo.2010.01.001

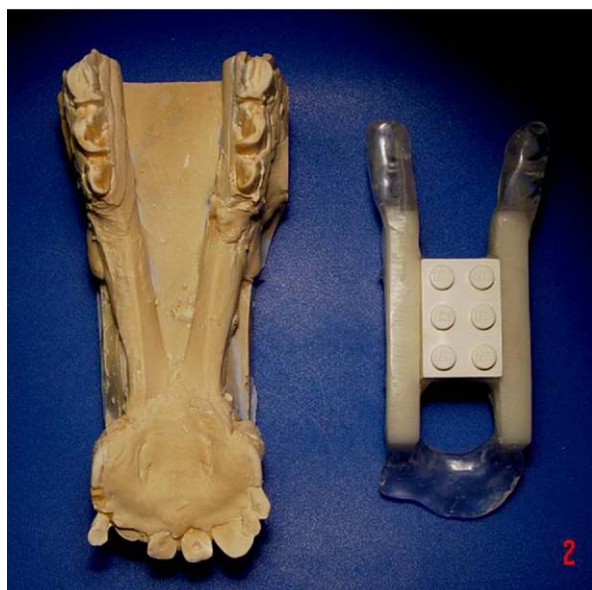

Fig. 1. Sheep mandible model and the acrylic guide.

brick serves for 3-dimensional calibration between the software and computerized tomography (CT), and for relocation of the guide to a positioning device (Hexapod; Schick Dental, Schemmerhofen, Germany) that enables insertion of guiding tubes into the guide (Fig. 2).

A cone-beam CT (I-Cat; Imaging Sciences, Hatfield, PA) of the sheep's mandible was taken with the guide affixed to the jaw and processed with 3-dimensional planning software (Med3D, Heidelberg, Germany). After determining the available bone and future location of the implants, a drill plan was processed and sent to the laboratory. In the drill plan, the exact location of each implant is represented by 12 values which calibrate the positioning device in placing 8 metal tubes 5 mm long and with diameters of 2 and 2.8 mm (for each site) into the roentgenic guide (Fig. 3).

Eight implants, 3.3 × 8 mm (BioCom; MIS Technologies, Shlomi, Israel), were placed in the direction and depth determined by the tubes. After placing the implants according to the drill plan a second CT scan of the sheep mandible was taken.

The drill plan figures of the planned implants were positioned using assigned software (Med3D) on the second CT scan to compare the implants position to the initial planning (Fig. 4). Values representing the implant locations of the original drill plan were compared with those of the placed implants using SPSS software (Chicago, IL).

RESULTS

Six measurements (3 vertical, 3 horizontal) were made on each implant to assess the deviation from the



Fig. 2. The positioning device.

initial implant planning. The vertical and horizontal deviations were measured (mm) at the implant shoulder (center), 9 mm above the shoulder (abutment), and at the implant apex. A repeated-measurement analysis of variance was performed comparing the location of measurement (abutment, shoulder, apex) and type of deviation (vertical vs. horizontal) (Table I). The statistical analysis yielded a significant effect of the type (vertical vs. horizontal) of deviation ($F(1,7) = 47.3; P < .001$), showing that the vertical deviation (mean -0.168 , SD 0.17) was significantly smaller than the horizontal deviation (mean 1.148 , SD 0.21).

At the implant shoulder (center), the mean vertical deviation was -0.17 mm and the mean horizontal deviation 0.99 mm ($P = .001$). At the abutment level, the mean vertical deviation was -0.12 mm and the mean horizontal deviation 1.04 mm ($P = .001$). At the apex level the mean vertical deviation was -0.22 mm and the mean horizontal deviation 1.41 mm ($P = .0002$) (Fig. 5).

DISCUSSION

Computer-aided surgery in dentistry is used for maxillofacial surgery and implant placement.¹⁵⁻²⁸ User-friendliness and cost contribute to the preferred use of computer-based surgical guides rather than navigators.⁷

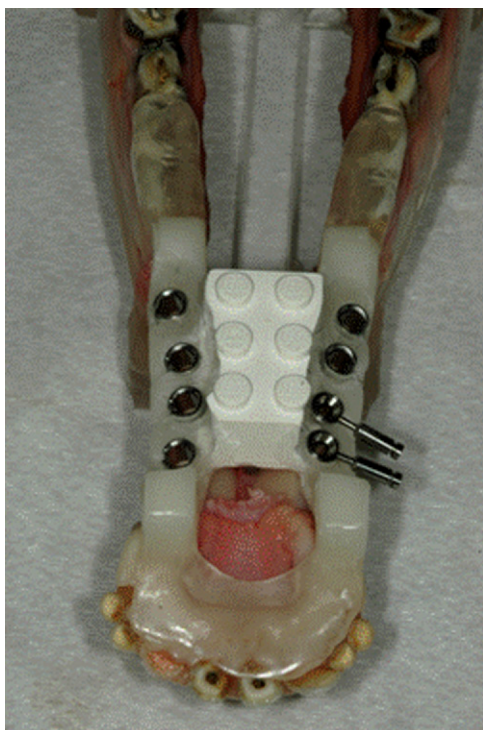


Fig. 3. Implants placement according to the metal tubes.

The accuracy of the system tested in the present study should be compared with the laboratory-based guide studies available in the literature^{8,24} to elucidate its potential clinical use. Fortin et al.⁸ used 3 dry bone and 1 plaster jaw models to determine the accuracy of inserting a 1.8 mm drill into a 2 mm surgical guide tube. Transfer error was <0.2 mm for translation and $<1.1^\circ$ for rotation. Those results show that this system has a high precision. However, that study assessed only the initial stage of the actual clinical work. Although it demonstrates the accuracy of the software, the drilling machine, and the interface between them, it lacks further inaccuracies resulting from further drilling up to implant insertion. The advantage of the present study is the use of a fresh bone model. Moreover, it demonstrated that most deviations from the initial planning occurred during implant placement. Another laboratory-based guide study, compared pre- and intraoperative data about implant length and diameter in 30 partially and fully edentulous patients treated with a laboratory-based guide systems.²⁴ Strong agreement was found between pre- and intraoperative data for both implant dimensions. However, that study did not examine the actual differences between the implant position in the preoperative planning and after placement. In the present study, the vertical match between the planned and placed implants positions were compared at 3 locations (implant

shoulder, abutment level, and apex level). The vertical differences between the planned and placed implants positions at the implant shoulder were within $0.04\text{--}0.83 \pm 0.17$ mm, at abutment level within $0.04\text{--}0.86 \pm 0.19$ mm, and at the implant apex within $0.04\text{--}0.84 \pm 0.16$ mm, mean -0.168 ± 0.17 . The horizontal differences between the planned and placed implants positions at the implant shoulder were within $0.43\text{--}1.66 \pm 0.15$ mm, at the abutment level within $0.66\text{--}1.57 \pm 0.13$ mm, and at the implant apex within $0.13\text{--}1.93 \pm 0.37$ mm, mean 1.148 ± 0.21 . For all implants, there was a greater horizontal discrepancy between the planned and the actual positions at the implant apex than at the implant head.

Results from the present study cannot be compared with the other laboratory guide-based systems studies, in which the pre- and postoperative data were not numerically compared. However, results can be compared to studies using stereolithographic-based systems. Di Giacomo et al.¹² compared differences between the location of the planned and placed implants in four patients. The guides were bone or tooth-bone supported. After implant placement, a second CT was taken, and software was used to fuse the implant images in the planning stage with the placed implant images. Differences in distance between planned and placed positions (1.45 mm at the implant shoulder and 2.99 mm at the apex) were higher than in the present study. Van Steenberghe et al.¹⁸ used bone-supported templates in 2 cadavers. After drilling and implant placement through the templates, a new CT scan was taken, and the planned and achieved implant locations and axes were compared. At the level of implant neck, the match was on average within 0.8 mm, and at the apex on average within 0.9 mm. Differences in distance between planned and achieved locations were most prominent in the horizontal direction of the implants (maximum 1.1 mm), similarly to the present study. In another study,¹⁰ comparing the accuracy of surgical drilling guides by placing 6 zygoma implants in 3 formalin-fixed human cadavers, preoperative CT images were matched with postoperative ones to assess the deviation between planned and installed implants. The largest deviation was 2.7 mm, found at the exit point of one of the implants. Those results are worse than the present study.

Sarment et al.⁹ conducted a study on 5 edentulous epoxy mandible models. On the right side a conventional surgical guide (control side) was used, and on the left, a stereolithographic guide (test side). Each jaw was CT scanned, and a registration method was applied to match it to the initial planning. Measurements included distances between planned implants and actual osteotomies. The average distance between the planned implant and the actual osteotomy was 1.5 mm at the entrance and 2.1 mm at the apex when the control guide was used. The

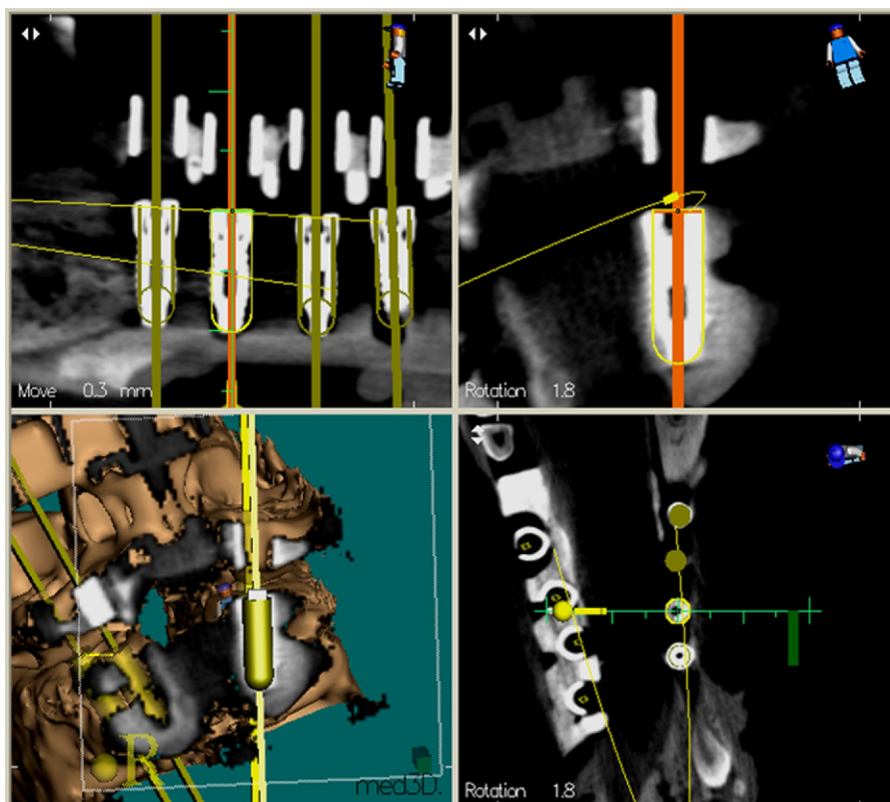


Fig. 4. The initial drill plan was positioned on the second CT scan.

Table I. Means and SDs of the deviations from planned locations among the 8 implants placed

Deviation from planned	Range	Mean	SD
Center level—vertical	0.04-0.83	0.17	0.17
Center level—horizontal	0.43-1.66	0.99	0.15
Abutment level—vertical	0.04-0.86	0.12	0.19
Abutment level—horizontal	0.66-1.57	1.04	0.13
Apex level—vertical	0.04-0.84	0.22	0.16
Apex level—horizontal	0.13-1.93	1.41	0.37

same measurements were significantly reduced to 0.9 mm and 1 mm when the test guide was used. Again, those results are worse than the present study.

The present study was conducted on a fresh jaw, in contrast to other studies in which dry jaws or plastic or stone models, were used.^{8,9,13-16,20} Fresh bone is a more accurate model, because it can be affected by factors such as implant system, size of bur steps, rotational speed, and guiding system, which can influence the final implant position.^{29,30} Stability and precise location of the surgical guide are crucial to the accuracy of the implant position.²³ Because the same guide is used for both imaging and surgery in the laboratory-based tested

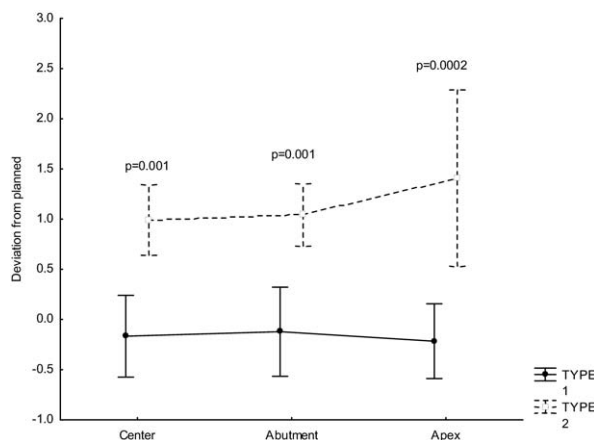


Fig. 5. Deviation from plan by location and type of deviation. The vertical bars represent range values. The *P* values represent the differences between vertical and horizontal deviations as assessed by Tukey HSD tests. Type 1 = vertical; type 2 = horizontal.

system, rigid fixation of the guide during roentgenographic examination and surgery with temporary implants could improve the accuracy and can be recom-

mended especially in extremely atrophic cases with limited bone volume.³¹

In conclusion, the data regarding the accuracy of the laboratory-based guide system investigated in the present study is better than or at least similar to the data regarding available computer-based guiding systems for dental implant placement. Further research is needed to validate its clinical accuracy and limitations.

The authors thank Mr. Izak Resnick from Model Dental Laboratory for his assistance.

REFERENCES

- Brånemark PI, Svensson B, van Steenberghe D. Ten-year survival rates of fixed prostheses on four or six implants ad modum Brånemark in full edentulism. *Clin Oral Implants Res* 1995;6:227-31.
- Adell R, Eriksson B, Lekholm U, Brånemark PI, Jemt T. Long-term follow-up study of osseointegrated implants in the treatment of totally edentulous jaws. *Int J Oral Maxillofac Implants* 1990;5:347-59.
- Jemt T, Lekholm U. Implant treatment in edentulous maxillae: a 5-year follow-up report on patients with different degrees of jaw resorption. *Int J Oral Maxillofac Implants* 1995;10:303-11.
- Smith DE, Zarb GA. Criteria for success of osseointegrated endosseous implants. *J Prosthet Dent* 1989;62:567-72.
- Widmann G, Bale RJ. Accuracy in computer aided implant surgery—a review. *Int J Oral Maxillofac Implant* 2006;21:298-304.
- Fortin T, Bosson JL, Isidori M, Blanchet E. Effect of flapless surgery on pain experienced in implant placement using an image guided system. *Int J Oral Maxillofac Implant* 2006;21:305-13.
- Vercruyssen M, Jacobs R, Van Assche N, Van Steenberghe D. The use of CT scan based planning for oral rehabilitation by means of implants and its transfer to the surgical field: a critical review on accuracy. *J Oral Rehabil* 2008;35:454-74.
- Fortin T, Champléoux G, Bianchi S, Buatois H, Coudert JL. Precision of transfer of preoperative planning for oral implants based on cone-beam CT-scan images through a robotic drilling machine. *Clin Oral Implants Res* 2002;13:651-6.
- Sarment DP, Sukovic P, Clinthorne N. Accuracy of implant placement with a stereolithographic surgical guide. *Int J Oral Maxillofac Implants* 2003;18:571-7.
- Van Steenberghe D, Malevez C, Van Cleynenbreugel J, Bou Serhal C, Dhoore E, Schutyser F, et al. Accuracy of drilling guides for transfer from three-dimensional CT-based planning to placement of zygoma implants in human cadavers. *Clin Oral Implants Res* 2003;14:131-6.
- Wanschitz F, Birkfellner W, Watzinger F, Schopper C, Patruta S, Kainberger F, et al. Evaluation of accuracy of computer-aided intra operative positioning of endosseous oral implants in the edentulous mandible. *Clin Oral Implants Res* 2002;13:59-64.
- Di Giacomo GA, Cury PR, de Araujo NS, Sendyk WR, Sendyk CL. Clinical application of stereolithographic surgical guides for implant placement: preliminary results. *J Periodontol* 2005;76:503-7.
- Hoffmann J, Westendorff C, Gomez-Roman G, Reinert S. Accuracy of navigation-guided socket drilling before implant installation compared to the conventional free-hand method in a synthetic edentulous lower jaw model. *Clin Oral Implants Res* 2005;16:609-14.
- Chiu WK, Luk WK, Cheung LK. Three-dimensional accuracy of implant placement in a computer-assisted navigation system. *Int J Oral Maxillofac Implants* 2006;21:465-70.
- Feng E, Gu L, Huang Y, Chang S. Computer-assisted surgical navigation system in dental implantology. *Int J CARS* 2006;1:417-9.
- Weihea S, Krusea C, Franza E-P, Bonitza L, Hassfelda S. A new planning and navigation system for dental implantology: evaluation of ergonomic aspects and accuracy. *Int J Comput Assist Radiol Surg* 2006;1:421-3.
- Ersoy AE, Turkyilmaz I, McGlumphy O, Ozan EA. Reliability of implant placement with steriolithographic surgical guides generated from computed tomography: clinical data from 94 implants. *J Periodontol* 2008;79:1339-45.
- Van Steenberghe D, Naert I, Andersson M, Brajnovic I, Van Cleynenbreugel J, Suetens P. A custom template and definitive prosthesis allowing immediate implant loading in the maxilla: a clinical report. *Int J Oral Maxillofac Implants* 2002;17:663-70.
- Nijmeh AD, Goodger NM, Hawkes D, Edwards PJ, McGurk M. Image-guided navigation in oral and maxillofacial Surgery. *British J Oral Maxillofac Surg* 2005;43:294-302.
- Casap N, Wexler A, Persky N, Schneider A, Lustmann J. Navigation surgery for dental implants: assessment of accuracy of the image guided implantology system. *J Oral Maxillofac Surg* 2004;62:116-9.
- Besimo CE, Lambrecht JT, Guindy JS. Accuracy of implant treatment planning utilizing template-guided reformatted computed tomography. *Dentomaxillofac Radiol* 2000;29:46-51.
- Klein M, Hein A, Luth, T, Bier J. Robot-assisted placement of craniofacial implants. *Int J Oral Maxillofac Implants* 2003;18:712-8.
- Wittwer G, Adeyemo WL, Schicho K, Gigovic N, Turhani D, Enislidis G. Computer-guided flapless transmucosal implant placement in the mandible: a new combination of two innovative techniques. *Oral Surg Oral Med Oral Pathol Oral Radiol Endod* 2006;101:718-23.
- Fortin T, Bosson JL, Coudert JL, Isidori M. Reliability of pre-operative planning of an image-guided system for oral implant placement based on 3-dimensional images: an in vivo study. *Int J Oral Maxillofac Implants* 2003;18:886-93.
- Mischkowski RA, Zinser MJ, Neugebauer J, Kübler AC, Zöller JE. Comparison of static and dynamic computer-assisted guidance methods in implantology. *Int J Comput Dent* 2006;9:23-35.
- Komiyama A, Klinge B, Hultin M. Treatment outcome of immediately loaded implants installed in edentulous jaws following computer assisted virtual treatment planning and flapless surgery. *Clin Oral Implants Res* 2008;19:677-85.
- Eggers G, Haag C, Hassfeld S. Image guided removal of foreign bodies. *Br J Oral Maxillofac Surg* 2005;43:404-9.
- Krause UHW, Nagel BM, Seibela RMM. A CT-based navigation system: Accuracy in phantom testing and first clinical experiences. *Int J Comput Assist Radiol Surg* 2006;1:169-87.
- Payer M, Kirmeyer R, Jakse N, Pertl C, Wegscheider W, Lorenzoni M. Surgical factors influencing mesiodistal implant angulation. *Clin Oral Implants Res* 2008;19:265-70.
- Akca K, Chang TL, Tekdemir I, Fanuscu MI. Biomechanical aspects of initial intraosseous stability and implant design: a quantitative micromorphometric analysis. *Clin Oral Impl Res* 2006;17:465-72.
- Holst S, Blatz MB, Eitner S. Precision for computer-guided implant placement: using 3D planning software and fixed intraoral reference points. *J Oral Maxillofac Surg* 2007;65:393-9.

Reprint requests:

Dr. Joseph Nissan
Department of Oral Rehabilitation
School of Dental Medicine
Tel-Aviv University
Tel-Aviv
Israel
nissandr@post.tau.ac.il